

Sulcal characteristics patterns and gyrification gradient at different stages of Anorexia Nervosa: A structural MRI evaluation

Enrico Collantoni^{a,1,*}, Christopher R. Madan^{b,1}, Valentina Meregalli^a, Paolo Meneguzzo^a,
 Enrica Marzola^c, Matteo Panero^c, Federico D'Agata^c, Giovanni Abbate-Daga^c,
 Elena Tenconi^{a,d}, Renzo Manara^a, Angela Favaro^{a,d}

^a Department of Neurosciences, University of Padua, Padova, Italy

^b School of Psychology, University of Nottingham, Nottingham, United Kingdom

^c Department of Neuroscience, University of Turin, Torino, Italy

^d Padua Neuroscience Center, University of Padua, Padova, Italy

ARTICLE INFO

Keywords:

Eating disorders
 Anorexia nervosa
 Neuroimaging
 Sulcal morphology
 Gyrification

ABSTRACT

Previous research evidenced alterations of different cortical parameters in patients with acute Anorexia Nervosa (AN), but no study to date investigated the morphology of individual sulci and their relationship with other structural indices. Our study aims at exploring the depth and width of 16 major cortical sulci in AN at different stages of the disorder and their relationships with the gyrification gradient. Two samples were included in the study. The first involved 38 patients with acute AN, 20 who fully recovered from AN, and 38 healthy women (HW); the second included 16 patients with AN and 16 HW. Sulcal width and depth were estimated for 16 sulci and outlined with a factorial analysis. An anterior-posterior gradient of gyrification was also extracted. Compared to HW, patients with acute AN displayed higher width and depth values in specific cortical sulci, and an altered gyrification gradient in areas encompassing the Central Sulcus, and Parieto-Temporal and Frontal Lobe regions. Sulcal width negatively correlated with gyrification gradient in areas where these values are altered in AN patients. Our results suggest the presence of alterations in sulcal morphology with a pattern similar to the gyrification gradient one and which seems to be related with malnutrition.

1. Introduction

Anorexia Nervosa is a severe psychiatric disorder with complex pathogenesis, which involves developmental, psychosocial, and biological factors (Zipfel et al., 2015). In recent years, many efforts have focused on investigating the neurobiological characteristics of AN, in the attempt to clarifying the complex interplay of state-dependent characteristics, neurodevelopmental trajectories, and disorder consequences (Couzins-Frankel, 2020; Favaro, 2013). Studies that evaluated brain morphology in the acute phases of AN highlighted alterations in various parameters that describe distinct cortical aspects, and that are differently related with both developmental and atrophic processes (Bernardoni et al., 2018; Collantoni et al., 2020b; Favaro et al., 2015; Lavagnino et al., 2016; Nickel et al., 2019). The two most considered indices in the cortical evaluation of AN are gyrification index (GI) and

cortical thickness (CT), which differ from each other in their stability/changing rates during development. In fact, while the gyrification index tends to remain stable throughout brain maturation (Armstrong et al., 1995; White et al., 2010), cortical thickness undergoes profound changes, especially during adolescence (Thambisetty et al., 2010). This different susceptibility to maturational and environmental factors makes GI and CT particularly useful in the evaluation of AN because they are likely to capture peculiar pathophysiological aspects characterizing the disorder (Cascino et al., 2020; Collantoni et al., 2019).

Nevertheless, in the wake of studies that considered novel cortical indices to better characterize the neurobiology of brain development and aging (Madan and Kensinger, 2018, 2016; McDonough and Madan, 2020; Sandu et al., 2014), recent research has included in the cortical evaluation of AN morphological parameters that offer a non-redundant description of the brain structure when compared to the more

* Corresponding author at: Department of Neurosciences, University of Padua, Via Giustiniani, 2 - 35128 Padova, Italy.

E-mail address: enrico.collantoni@unipd.it (E. Collantoni).

¹ Enrico Collantoni and Christopher R. Madan equally contributed to this work.

conventional ones. The evaluation of absolute mean curvature (AMC), fractal dimension (FD) and sulcal depth (SD), besides CT and GI, have allowed more in-depth considerations about the structural changes of the brain in AN, and contribute in highlighting that the acute phases of the disorder are likely to be characterized by a flattening of the cortex and an associated reduction in sulcal depth (Bernardoni et al., 2018; Collantoni et al., 2020b; Nickel et al., 2019; Schultz et al., 2017).

The evidence of a cortical flattening during adolescence is well established in the literature (Alemán-Gómez et al., 2013). This mechanism seems to be driven by a simultaneous decrease in SD and an increase in sulcal width (SW) over time, which goes along with a reduction in CT. Modification in sulcal morphology during brain maturation has been hypothesized to account for the age-related stability of GI, as it is likely that sulcal widening compensates the decrease in SD, thus keeping the ratio between total and exposed surface quite constant (Kochunov et al., 2005; Magnotta, 1999). Therefore, it is possible to hypothesize that the alteration in GI evidenced in acute phases of AN, as well as its substantial normalization after weight gain, could be linked to a variation in the ratio between these two indices, or to an alteration of their developmental trajectories due to disorder-related factors. Furthermore, since these two indices' morphological changes are likely to be correlated, it is conceivable that their alterations follow a similar topological pattern.

Visual assessment of sulcal widening have long been used to clinically reveal signs of cortical atrophy in different medical conditions, and in AN as well (Artmann et al., 1985). Of particular interest, in the evaluation of sulcal morphology, is that sulcal abnormalities are likely to integrate atrophy of both gray matter and of the surrounding gyral white matter, thus showing sensitivity to different pathogenic processes that may occur at different stages of the disorder. AN seems to be characterized, after the earliest stages, by a neurobiological progression that profoundly reflect on its prognostic features (Treasure et al., 2015). Therefore, as the disorder progresses, morphological cortical alterations are likely to become more pronounced, strengthening the relationship between gyrification abnormalities and sulcal morphology. In particular, alongside the disorder progression, a similarly localized pattern of reduced cortical gyrification and sulcal morphology is expected. In this regard, it is important to consider that previous studies investigating patients with a short illness duration did not reveal significant cortical morphology abnormalities (Lavagnino et al., 2016), thus suggesting that these may occur in later stages of the disorder.

In light of all these considerations, the main aim of our study was to evaluate sulcal width and depth in 3 groups of patients with AN: one with a recent onset (less than one year), one with longer duration of illness (more than one year), and one after full remission of the disorder. Secondly, we examined, in the different stages of the disorder, how sulcal morphology related with the topography of cortical gyrification and its association with clinical variables. To better verify the presence of a topographical correspondence between the alterations in cortical gyrification and in sulcal morphology, we have extracted and plotted an anterior-posterior gyrification gradient of the entire cortex. We hypothesized the presence of a more pronounced sulcal widening and a reduction in sulcal depth in patients with AN, with a direct and significant association with the BMI and with the disorder stages. Furthermore, we hypothesized a specific pattern of relationships between sulcal morphology and cortical gyrification topography in AN: an inverse correlation between gyrification and sulcal width, and a positive correlation between gyrification and sulcal depth in areas where both measures are significantly altered.

2. Methods

2.1. Sample characteristics and clinical assessment

The sample included was similar to a previous study (Collantoni et al., 2020a). A total of 74 patients with AN (54 with acute AN and 20

fully recovered (recAN)), and 54 HW were recruited from two sites.

Site 1. Patients of the Padova site included 58 patients with AN (38 with acute AN and 20 in full remission) and 38 HW. From the acute AN sample, 32 subjects were affected by the restricting subtype and 6 by the binge-purging subtype. 7 patients presented restrictive AN subtype with a history of binge eating or purging behaviors. The sample included was the same as in a previous study (Collantoni et al., 2020b; Favaro et al., 2013). Patients were recruited from the Padova Hospital Eating Disorders Unit, were assessed using the Structured Clinical Interview for DSM-5 (American Psychiatric Association et al., 2013), and recruited if meeting full criteria for AN. The mean age of the patients was 26.1 years (SD=7.2), ranging from 15.5 to 40.5 years old. A sample of HW similar to the patient group in age, hand lateralization, educational level, and ethnicity was recruited from the same geographical area.

Patients who recovered from AN (recAN) were recruited according to the following criteria: 1) having had AN (according to DSM-5 criteria) in their lifetime; 2) being asymptomatic for at least six months at the time of scanning (mean remission time: 38.5 months (standard deviation = 33.2; range 6–96)). Exclusion criteria for the recovered group were: 1) food restriction; 2) bingeing, 3) excessive exercise; 4) fasting and purging in the last 6-months; 5) Amenorrhea. None of recovered-group participants relapsed in the year following the scanning.

Site 2. Patients of the Turin site were consecutively recruited at the Outpatient Program of the Center for Eating Disorders of the University of Turin if meeting full criteria for AN, as assessed with the Structured Clinical Interview for DSM-5 by an experienced psychiatrist. The mean age of the patients was 21.2 years (SD=4.3), ranging from 18 to 33 years old. A sample of HW similar to the patient group in age, hand lateralization, educational level, and ethnicity was recruited from the same geographical area. A total of 16 patients with AN and 16 HW were finally enrolled; all the patients were affected by the restricting subtype.

Written informed consent was provided by all participants. This study was approved by the Ethical Committees of the "Città della Salute e della Scienza" Hospital of Turin and of the Hospital of Padova. Table 1 describes the main characteristics of the sample.

Exclusion criteria for patients with AN and HW in both sites were the following: 1) male gender; 2) current or lifetime neurological diseases; 3) moderate mental impairment (IQ < 60) or learning disabilities; 4) active suicidality or major depression; 4) bipolar disorder or schizophrenia spectrum disorder; 5) history of drug/alcohol dependence; 6) pregnancy; 7) known contraindications to conventional MRI, past or present use of medications (for HW).

2.2. Magnetic resonance acquisition

At both site 1 and 2 data were acquired on Philips Achieva 1.5 Tesla MRI scanners equipped for echo-planar imaging and with 8 channels optimized head SENSE coils. The sequences acquired were 3D sagittal T1-weighted gradient echo.

At site 1, RF spoiled Incoherent Gradient Echo (Philips acronym 3D-FFE, 3D Fast-Field Echo) were acquired with the following parameters: voxel size $0.66 \times 0.66 \times 1$ mm³, TE = 3.8 ms, TR = 20 ms, Flip Angle = 20°, Matrix 320×320 , FOV = 210 mm, pixel BW = 189 Hz, 160 slices of 1 mm, SENSE = 1.3×1.6 , duration 7–9 min.

At site 2, Ultrafast 3D Gradient Echo (Philips acronym 3D-TFE, 3D Turbo-Field Echo, Siemens acronym MP-RAGE, Magnetization Prepared Rapid Acquisition Gradient Echo) were acquired with the following parameters: voxel size = $1 \times 1 \times 1$ mm³, TE = 3 ms, TR = 7 ms, Flip Angle = 8°, Matrix 256×256 , FOV = 256 mm, pixel BW = 241 Hz, 190 slices of 1 mm, SENSE = 1×3 , duration 4–5 min.

2.3. Data processing and statistics

Data processing was performed using the FreeSurfer package (Martinos Center for Biomedical Imaging, Massachusetts General Hospital, Boston) version 5.3.0 (Fischl, 2012). The preprocessing was carried out

Table 1

. - Characteristics of the samples at the two study sites.

	site 1			AN vs HW	RecAN vs HW	site 2			ANsite1 vs ANsite2	HCsite1 vs HC site2
	AN (n = 38)	HW (n = 38)	RecAN (n = 20)			AN (n = 16)	HW (n = 16)	AN vs HW		
Age (years)	26.1 (7.2)	25.3 (6.3)	26.3 (7.1)	0.54 (0.59)	0.59 (0.56)	21.2 (4.3)	22.5 (2.4)	1.06 (0.30)	2.55 (0.01)	1.70 (0.10)
Body mass index	15.8 (1.8)	21.7 (2.9)	19.6 (1.6)	10.51 (<0.001)	2.91 (0.005)	16.1 (1.2)	21.6 (2.4)	8.10 (<0.001)	0.22 (0.59)	0.12 (0.91)
Education (ys)	14.3 (2.3)	15.4 (2.3)	14.2 (2.7)	2.44 (0.02)	1.97 (0.05)	14.6 (2.1)	15.7 (2.0)	1.57 (0.13)	0.41 (0.68)	0.45 (0.66)
Duration of illness (months)	78.6 (81.3)	=	45.7 (65.0)	=	=	8.8 (3.1)	=	=	3.41 (0.001)	=
Age at onset (years)	18.3 (5.1)	=	17.7 (3.2)	=	=	20.2 (4.3)	=	=	1.27 (0.21)	=

Legend: AN: anorexia nervosa; HW: healthy women; RecAN: recovered AN patients.

according to the standard procedure using the following steps: skull-stripping and intensity correction, determination of the gray matter–white matter boundary for each cortical hemisphere using tissue intensity and neighborhood constraints, tessellation of the resulting surface boundary to generate multiple vertices across the whole brain before inflating. Surface reconstruction and segmentation were inspected. Minor manual intervention was performed according to FreeSurfer guidelines.

Sulcal morphology. Sulcal width and depth were estimated for 16 major sulci using the calcSulc toolbox (Madan, 2019). The considered sulci are the Central, Post-Central, Inferior Frontal, Superior Frontal, Parieto-Occipital, Middle Occipital and Lunate, Occipito-Temporal, and Marginal Part of the Cingulate sulci, in both hemispheres. We conducted analysis on individual sulcal measures and also performed a factor analysis, in order to perform between-groups comparisons between those factors that better explained the variance from the data.

Gyrification topography. To evaluate the topographical distribution of cortical gyrification an anterior-posterior gyrification pattern

was extracted and plotted separately in both experimental and control groups based on recently developed method (Madan, 2021). The gyrification measurements for each MRI session (Schaefer et al., 2012) were resampled to the common surface space using FreeSurfer's spherical surface co-registration (Fischl et al., 1999), and then mean gyrification values were simplified in an anterior-posterior plot after dividing the surface space in 200 coronal sections (as described in Madan, 2021).

All the data were adjusted for age and site of acquisition using linear regressions and saving residuals. Group comparisons were performed by means of GLM. Correlations were performed using Spearman's ρ (rho). Given the high number of correlations and the fact that the morphological data could be related with each other, we considered the correlation results significant at a threshold of $p < 0.008$, false discovery rate (FDR) corrected. However, given the exploratory nature of the research and considering that the present is the first paper exploring the morphology of specific cortical sulci and their relationship with the anterior-posterior gyrification gradient, we have also reported the uncorrected correlation values. Correlation values exceeding the FDR

Table 2

Sulcal width (mm) for all groups.

Sulcus name	Hem	AN Mean (SD)	recAN Mean (SD)	HW Mean (SD)	ANOVA F (p)	Post-hoc Bonferroni adjusted p-value
Central	L	2.62 (0.42)	2.19 (0.30)	2.27 (0.38)	13.91 (<0.001)	AN > recAN, $p = 0.003$ AN > HW, $p < 0.001$
	R	2.55 (0.36)	2.18 (0.31)	2.27 (0.36)	9.67 (< 0.001)	AN > recAN, $p = 0.007$ AN > HW $p < 0.001$
Post-Central	L	3.22 (0.53)	2.86 (0.45)	2.80 (0.50)	9.33 (< 0.001)	AN > HW, $p < 0.001$
	R	3.09 (0.51)	2.65 (0.34)	2.66 (0.46)	11.94 (< 0.001)	AN > recAN, $p = 0.008$ AN > HW, $p < 0.001$
Superior Frontal	L	3.17 (0.53)	2.90 (0.73)	2.95 (0.55)	2.86 (0.061)	
	R	3.14 (0.66)	2.91 (0.63)	3.15 (0.77)	0.38 (0.688)	
Inferior Frontal	L	2.62 (0.62)	2.51 (0.71)	2.55 (0.62)	0.20 (0.816)	
	R	2.40 (0.51)	2.11 (0.39)	2.29 (0.63)	1.28 (0.286)	
Parieto-Occipital	L	2.52 (0.39)	2.14 (0.28)	2.30 (0.44)	6.08 (0.003)	AN > recAN, $p = 0.006$ AN > HW, $p = 0.035$
	R	2.64 (0.50)	2.18 (0.32)	2.37 (0.37)	7.35 (0.001)	AN > recAN, $p = 0.005$ AN > HW, $p = 0.007$
Occipito-Temporal	L	2.05 (0.43)	2.04 (0.34)	2.02 (0.36)	0.07 (0.937)	
	R	1.97 (0.46)	2.04 (0.31)	2.02 (0.43)	0.33 (0.780)	
Middle Occipital and Lunate	L	1.77 (0.38)	1.63 (0.45)	1.69 (0.42)	0.60 (0.549)	
	R	1.60 (0.40)	1.39 (0.39)	1.51 (0.32)	1.43 (0.243)	
Marginal part of Cingulate	L	2.17 (0.34)	1.94 (0.29)	1.98 (0.32)	5.92 (0.004)	AN > recAN, $p = 0.044$ AN > HW, $p = 0.007$
	R	2.33 (0.36)	2.16 (0.45)	2.06 (0.35)	6.99 (0.001)	AN > HW, $p = 0.001$

adjusted threshold are discussed as statistical tendencies.

A vertex-wise analysis of gyrification was also conducted and reported in Supplementary Materials.

3. Results

3.1. Sulcal morphology

Table 2 shows the average sulcal width values of the three groups. Patients with acute AN displayed significantly higher width values in left and right Central, Post-Central, Parieto-Occipital and Pars Marginalis of Cingulate Sulcus compared to HW. Patients with acute AN showed significantly higher depth values in the left Pars Marginalis of the Cingulate Sulcus compared to HW ($F(2125) = 6.85, p = 0.001$). No other significant differences in sulcal depth values were detected between patients with acute AN and HW (Table S2).

For both sulcal width and depth, no statistically significant differences emerged in the comparison between recAN and HW, indicating that recovering from anorexia allowed the brain to return to a similar state as the healthy individuals.

3.2. Anterior-posterior gradient in gyrification

The results of the gyrification gradient are shown in Fig. 1. As displayed in the figure, the gradient in the three groups follows a similar pattern, demonstrating that the overall distribution of gyrification does not change in AN, where it is only diminished in magnitude. Interestingly, AN is associated with overall decreases in gyrification gradient, which is, however, significantly reduced in areas encompassing the Central Sulcus, Parieto-Temporal regions, and Frontal Lobe ones in acute AN when compared to HW.

3.3. Factor analysis

To better interpret sulcal morphology values, we conducted an exploratory factor analysis. The purpose of the analysis was to summarize the data of all sulcal measures and to determine the latent factors influencing them. A further aim of this analysis was to better identify the topographic patterns of cortical alteration, also maximizing the associations between sulcal morphology, gyrification, and clinical variables.

Sulcal Width. Results of Bartlett's test of sphericity support the existence of factors within the data $\chi^2 = 314.495, p < .001$. Thus, we conducted the analysis using a principal component analysis extraction with an orthogonal (varimax) rotation method. The Kaiser's (K1) criterion pointed out the presence of six factors that accounted for more than 60% of the total variance. Only factor loadings above 0.40 (or below -0.40) were considered to meet the minimal level for interpretation of factor structure.

Rotation factor loadings for sulcal width are reported in Table 3. Sulci that salient loading on by Factor 1 included the right Post-central

Sulcus, the right Pars Marginalis of Cingulate Sulcus and Central Sulcus bilaterally; Factor 2 was loaded on by right and left Parieto-Occipital sulcus, left Inferior Frontal sulcus, and left Post-Central sulcus; Factor 3 was loaded on by Occipito-Temporal and Middle Occipital sulci bilaterally; Factor 4 was loaded on by left Central and Superior Frontal sulci; factor 5 was loaded on by Superior Frontal sulcus bilaterally, and left Pars Marginalis of Cingulate Sulcus; factor 6 was loaded on by left Occipito-Temporal and Inferior Frontal sulci.

Sulcal Depth. Results of Bartlett's test of sphericity support the existence of factors within the data $\chi^2 = 404.529, p < .001$. The Kaiser's criterion and the scree plot pointed out the presence of six factors, that accounted for more than 60% of the total variance. Rotation factor loadings for SW are reported in Table 4. Factor 1 was loaded on by Pars Marginalis of Cingulate sulcus and Parieto-Occipital sulcus bilaterally; Factor 2 was loaded on by left and right Inferior Frontal sulcus, right Superior Frontal sulcus, and left Post-Central sulcus; Factor 3 was loaded on by Occipito-Temporal sulcus bilaterally, Factor 4 was loaded on by left Post-Central sulcus and Central Sulcus bilaterally; Factor 5 was loaded on by left Superior Frontal and right Post-Central sulci; Factor 6 was loaded on left Post-central, right Central, and left and right Middle-Occipital sulci. Total variance explained by every single factor is reported in supplementary Tables 2 and 3.

Between-group comparison revealed statistically significant differences in the first loaded factor ($F(2125) = 14.107, p < 0.001$) and in the second loaded factor ($F(2125) = 5.860, p = 0.004$) computed on SW values. Post-hoc analyses showed significant differences between acute AN patients and both recAN ($p = 0.016, p = 0.008$) and HW ($p < 0.001, p = 0.036$).

Between group comparisons computed on SD values revealed significant differences in the first loaded factor ($F(2125) = 3.885, p = 0.023$) and in the fifth loaded factor ($F = 3.770, p = 0.026$). Post hoc analyses showed significant differences between acute AN and HW ($p = 0.038, p = 0.023$).

Correlation analysis detected the presence of a positive correlation between BMI and the third factor computed on SD ($\rho = 0.364, p = 0.007$). Moreover, the duration of the disorder positively correlated with the first SW factor ($\rho = 0.441, p = 0.007$) and negatively correlated with the fifth SD factor ($\rho = -0.426, p = 0.008$). No other significant associations between factors computed on sulcal morphology values and BMI, illness duration and age of onset of the were present.

3.4. Gyrification gradient and sulcal morphology in patients with short duration of an vs long duration of an

To further explore the effects of duration of illness on sulcal width and depth we divided the sample in patients with a short duration of illness (Short AN) (equal to or less than 1 year) and patients with a longer durations (Long AN). The control group was divided to compare groups of similar age and site of scanning. The short-AN group ($n_{AN} = 23, n_{HC} = 24$.) had an average duration of 8.7 ± 3.0 months (age:

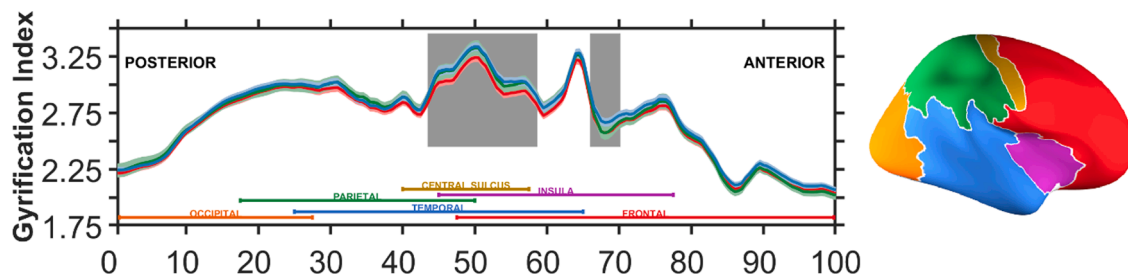


Fig. 1. Gyrification index across posterior (percentile 0; caudal) to anterior (percentile 100; rostral). The red line represents the distribution of gyrification gradient in patients with acute AN; the green line represents the recAN group; the blue line represents the HW. For ease of interpretation, colored labels are included at the bottom, denoting each of the four lobes, insula, and central sulcus, along with an inflated brain (right panel) with the same coloring (also see Madan, 2021). grey boxes identify the areas where the differences in gyrification gradient are significantly different in acute AN patients and HW at $p < 0.005$ -uncorrected.

Table 3
Sulcal width factor analysis.

Sulcus Name	Factor						Communality
	1	2	3	4	5	6	
Marginal part of Cingulate R	0.768						0.665
Post-Central R	0.661						0.507
Central R	0.690						0.699
Central L	0.614			0.422			0.665
Parieto-Occipital R		0.690					0.610
Parieto-Occipital L		0.565					0.457
Inferior Frontal R		0.648					0.425
Occipito-Temporal R			0.618				0.396
Occipito-Temporal L			0.613			0.476	0.652
Middle Occipital and Lunate L			0.598				0.442
Middle Occipital and Lunate R			0.591				0.575
Superior Frontal L				0.824			0.721
Superior Frontal R					-0.736		0.756
Post-Central L		0.442				0.584	0.664
Marginal part of Cingulate L					0.457		0.535
Inferior Frontal L						0.774	0.683

Table 4
Sulcal depth factor analysis.

Sulcus Name	Factor						Communality
	1	2	3	4	5	6	
Marginal Part of Cingulate L	0.752						0.639
Marginal Part of Cingulate R	0.722						0.660
Parieto-Occipital L	0.697						0.658
Parieto-Occipital R	0.684						0.621
Inferior Frontal R		0.766					0.677
Inferior Frontal L		0.749					0.616
Superior Frontal R		0.539					0.598
Post-Central L		0.483		0.441		-0.423	0.659
Occipito-Temporal L			0.870				0.796
Occipito-Temporal R			0.849				0.767
Central L				0.739			0.689
Central R				0.659		0.413	0.733
Superior Frontal L					0.789		0.716
Post-Central R					0.644		0.620
Middle Occipital and Lunate R						0.740	0.647
Middle Occipital and Lunate L						0.640	0.476

19.7 ± 4.0 vs. 21.3 ± 2.9 years; body mass index: 15.9 ± 1.3 vs. 21.9 ± 2.4 kg/m²; 7 patients and 8 healthy women were scanned at Site 1. The long-AN group (n AN=31, n HC=30) had an average duration of 93.9 ± 82.6 months (age: 27.8 ± 6.9 vs. 27.0 ± 5.9 years; body mass index 15.9 ± 1.8 vs. 21.4 ± 3.1 kg/m²; all patients and all healthy women were scanned at site 1).

Results of gyrification gradient are shown in Fig. 2. Gyrification gradient showed two clusters of alteration in the Long AN group when compared to HW, while the Short AN group showed only one and more confined cluster of alteration.

Table 5 shows the comparisons between Short AN group and HW and Long AN group and HW in sulcal width values. Patients with a short duration of the disorder showed significantly higher width values in left and right Central and Post-Central sulci, in right Parieto-Occipital sulcus and in right Pars Marginalis of the Cingulate Sulcus when compared to HW. Patients with a long duration of the disorder showed higher width values in right Post-Central sulcus and in Central, Parieto-Occipital and Pars Marginalis of Cingulate sulci bilaterally.

The comparisons between Short AN group and HW and Long AN group and HW in sulcal depth values showed higher depth values in the left Pars Marginalis of the Cingulate sulcus in patients with short duration of the disorder (F(1,43) = 5.079, *p* = 0.029), and higher depth values in the left and right Pars Marginalis of the Cingulate sulcus in patients with a long duration of the disorder (F(1,58) = 10.321, *p* = 0.002), (F(1,58) = 5.391, *p* = 0.024) (Table 4 in supplementary materials). Differences in sulcal width and depth between patients with AN and HW in Sites 1 and 2 are reported in supplementary Tables 5 and

Table 6.

A comparison between patients with a short duration of the disorder and HW revealed the presence of a significant difference in the first (F(1,40) = 6.007, *p* = 0.019), fourth (F(1,40) = 5.105, *p* = 0.029), and fifth (F(1,40) = 8.025, *p* = 0.007) factors computed on width. A tendency toward significance also emerged for the second factor (F(40,1) = 4.017, *p* = 0.052). No statistically significant differences emerged in a comparison between Short AN group and HW in factors computed on depth. A comparison between the Long AN group and HW revealed the presence significant differences first factor computed on width (F(1,56) = 16.021, *p* < 0.001) and in the first and fifth factors computed on depth (F(1,58) = 7.053, *p* = 0.010; F(1,58) = 5.767, *p* = 0.020).

An uncorrected correlation analysis detected the presence of positive correlations between the first two factors computed on SW and duration of the disorder in the Long AN group (rho = 0.391, *p* = 0.036; rho = 0.422, *p* = 0.023), and a negative correlation between the disorder duration and the fifth loaded factor computed on sulcal depth (rho = -0.357, *p* = 0.049). No loaded factors computed on sulcal width showed correlations with the duration of the disorder in the Short AN group, while a negative correlation between the disorder duration and the sixth loaded factor computed on sulcal depth was evidenced in patients with shorter duration of AN (rho = -0.772, *p* = 0.042). Moreover, a negative correlation between BMI and the third factor computed on sulcal width (rho = -0.536, *p* = 0.012) and a positive correlation between the third factor computer on sulcal depth were evidenced in the Short AN group (rho = 0.496, *p* = 0.016). No other significant correlation between factors computed on sulcal width and depth and clinical values emerged

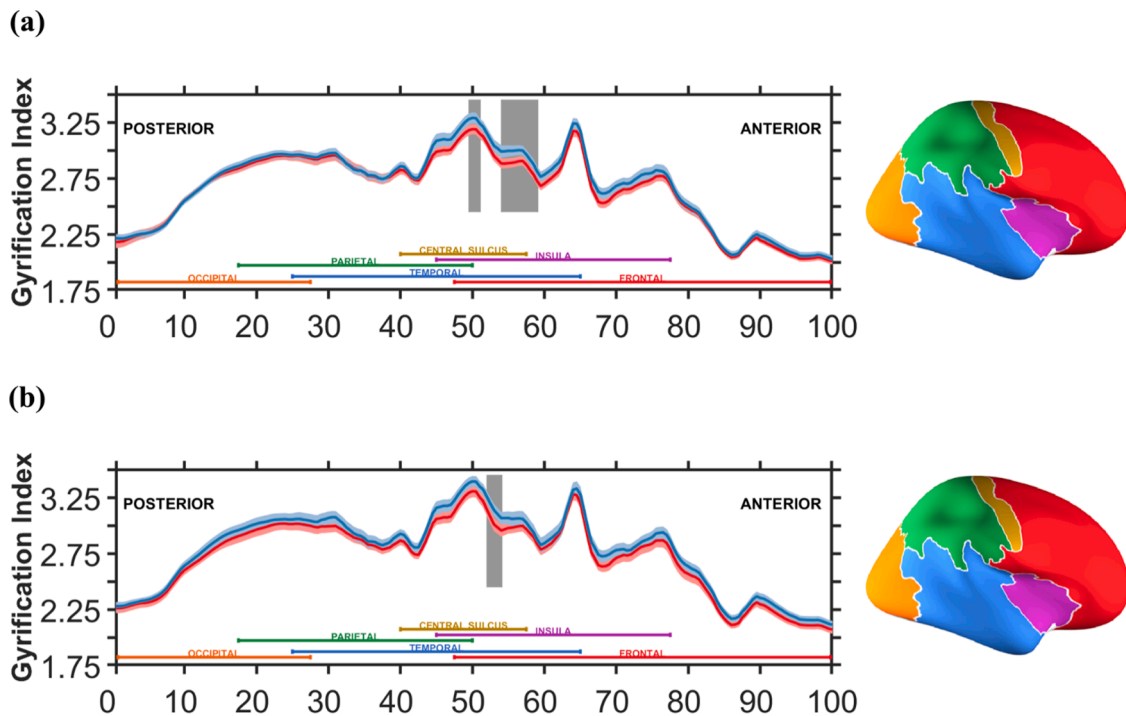


Fig. 2. Gyrification index across posterior (percentile 0; caudal) to anterior (percentile 100; rostral). In figure (a) the red line represents the distribution of gyrification gradient in patients with duration of the disorder longer than 1 year, while the blue line represents the HW. In figure (b) the red line represents the distribution of gyrification gradient in patients with duration of the disorder shorter than 1 year, while the blue line represents the HW. gray boxes identify the areas where the differences in gyrification gradient are significantly different in acute AN patients and HW at $p < 0.005$ -uncorrected.

Table 5
Effects of illness duration on sulcal width.

Sulcus Name	Hem	Short Duration (< 1 year) 23 AN vs. 24 HW		Long Duration (> 1 year) 31 AN vs. 30 HW	
		F(p)	Effect size d	F(p)	Effect size d
Central	L	7.04 (0.011)	0.80	15.33 (<0.001)	1.05
	R	7.18 (0.010)	0.78	9.80 (0.003)	0.82
Post-Central	L	23.55 (<0.001)	1.31	3.29 (0.075)	0.48
	R	5.40 (0.025)	0.65	16.38 (<0.001)	1.05
Superior Frontal	L	2.88 (0.097)	0.43	2.13 (0.150)	0.37
	R	0.47 (0.496)	-0.19	0.45 (0.504)	0.15
Inferior Frontal	L	0.33 (0.566)	-0.22	1.25 (0.268)	0.29
	R	4.00 (0.052)	0.56	0.13 (0.721)	-0.05
Parieto-Occipital	L	2.58 (0.115)	0.49	5.31 (0.025)	0.59
	R	4.63 (0.037)	0.63	5.81 (0.019)	0.63
Occipito-Temporal	L	0.04 (0.837)	-0.05	0.76 (0.387)	0.23
Middle Occipital and Lunate	R	0.02 (0.900)	0.08	0.79 (0.378)	-0.23
	L	0.34 (0.566)	0.22	0.80 (0.375)	0.22
Marginal part of Cingulate	R	0.03 (0.854)	0.03	3.67 (0.061)	0.47
	L	4.17 (0.047)	0.50	6.03 (0.017)	0.66
	R	9.99 (0.003)	0.90	6.05 (0.017)	0.62

in the Short AN and Long AN groups.

3.5. Correlation between gyrification gradient, sulcal morphology, and clinical indices

An uncorrected correlation analysis between the values of the section where gyrification gradient is altered in the whole AN, short AN, and long AN groups and results of factor analysis evidenced the presence of negative correlations between the first factor computed on SW and gyrification in the whole AN sample ($\rho = -0.298, p = 0.036$) and in the long-AN one ($\rho = -0.298, p = 0.042$), and between the second factor computed on SW and gyrification in the Short AN sample ($\rho = -0.564, p = 0.008$). Positive correlation between second factor on SD and gyrification in the whole sample ($\rho = 0.346, p = 0.010$).

Negative correlations emerged between gyrification gradient and the duration of the disorder in the whole AN group and in the Long AN one ($\rho = -0.540, p = .000; \rho = -0.494, p = 0.005$), and between gyrification gradient and the age of onset of the disorder in the Short AN group ($\rho = -0.439, p = 0.036$).

4. Discussion

In this study, we evaluated sulcal width and depth of 16 main brain sulci in AN, also trying to disentangle the relationships between any change in sulcal morphology and gyrification gradients across different stages of the disorder. Our results showed a higher sulcal prominence in patients with AN when compared to HW, which reached a statistical significance in Central, Post-Central, Parieto-Occipital, and Pars Marginalis of Cingulate sulcus bilaterally. Nevertheless, in contrast with previous findings, our study did not evidence a significant reduction in sulcal depth in the experimental sample (Bernardoni et al., 2018; Nickel et al., 2019). Instead, our results highlighted that the left Pars Marginalis of the Cingulate sulcus was significantly deeper in patients with AN compared to HW. The already evidenced association between cortical gyrification and sulcal morphology in healthy as well as in clinical

populations (Janssen et al., 2014; Kochunov et al., 2005; Magnotta, 1999; (White et al., 2003) suggested the opportunity of investigating the presence of possible relationships between sulcal measures and gyrification ones. Since the alterations in sulcal width showed to be topologically confined in central and post-central areas of the cortex, we analyzed the topographical disposition of gyrification in an anterior-posterior gradient that allowed us to better visualize if alterations of these two indices are similarly distributed across the cortex.

The observation that a significant reduction in gyrification gradient tends to localize in those areas that are characterized by higher sulcal widening indicates and confirms that these cortical alterations in AN are not widespread to the whole cortex (Favaro et al., 2015; Lavagnino et al., 2018). Moreover, it supports the usefulness of investigating the complex brain alterations underlying the neurobiology of the disorder using different indices that can capture distinct aspects of cortical morphology, but whose changes are likely to be subtended by similar pathogenetic processes (King et al., 2018).

To better characterize the topological patterns in which the individual sulcal morphology is organized, we conducted a factor analysis that showed the presence of six latent factors for both sulcal width and depth. A between-group comparison conducted on these factors confirmed the presence of a significant widening of sulci that are localized in areas encompassing temporal, parietal, and central sulcus regions. Interestingly, in line with the comparisons of individual sulci measures in patients with AN and HW, this analysis showed a significant difference in a factor encompassing sulci that are deeper in the experimental group than in control one. The increased depth that some of the examined sulci showed in patients with acute AN compared to HW differs from findings of previous studies (Bernardoni et al., 2018; Nickel et al., 2019) and is partially divergent with the hypothesis that changes in sulcal morphology are associated with a flattening of the cortex. Therefore, this observation should be further investigated by relating the sulcal morphological characteristics to other cortical parameters (e.g., using methods similar to Miller et al., 2021).

To better explore the relationship between changes in sulcal morphology and gyrification gradient, we conducted a correlation analysis between these two indices, that showed a trend toward an inverse association between the first loaded factor computed on sulcal width (which encompass the central sulcus bilaterally, the right post-central and the pars marginalis of the cingulate sulci) and the section where gyrification gradient showed to be more altered in the acute AN group. A negative association between increased sulcal prominence and gyrification was already evidenced by Janssen et al. (2014) in the frontal lobe of a sample of adolescent patients with schizophrenia, which allowed hypothesizing a causal relationship between the modification patterns of these two indices. Similar to schizophrenia, the etiology of AN seems to be characterized by alterations in neurodevelopmental trajectories (Favaro, 2013). Still, brain structural modifications in this disorder are also likely to be profoundly associated with the effects of malnutrition. For these reasons, examining the morphology of cortical sulci and their relationship with gyrification patterns can be highly helpful in better disentangling the complex neurobiology of AN.

Interestingly, there is a trend toward a positive correlation between the gyrification gradient and the second loaded factor calculated on the depth of the sulcus (which encompass the inferior frontal sulcus bilaterally, the right inferior frontal and the left post-central sulci), supporting the presence of an inverse association between gyrification and the different morphological characteristics of the sulci. This complex relationship between sulcal morphology and gyrification is interesting and deserves to be further investigated by future research. In fact, if sulcal width has increased more significantly than sulcal depth, as appears to be evidenced by our results, the exposed cortical surface should increase, and gyrification index with it (Kochunov et al., 2005). It could be hypothesized that the enlargement of the main sulci coincides with an overall reduction in the complexity of specific cortical areas, which in turn may be due to a flattening of minor sulci that have not been

investigated in the present research.

The analysis of how sulcal morphology varied according to the different stages of AN showed similar alterations in the groups of patients with different disorder durations, suggesting the absence of a clear effect of the duration of the illness on the structural modification of the sulci. The presence of a less distributed alteration in gyrification gradient evidenced by the comparison between the Short AN group and the HW one, than the one displayed by the comparison between Long AN group and HW suggests that longer duration of the disorder may have a greater impact on the cortical structure. Furthermore, The significant association between the duration of the disorder and the morphology of specific sulci and gyrification gradient in the whole AN group and in the Long AN one suggests an effect of the disorder duration on cortical morphological that deserves to be further investigated by future research. However, it is worth noting that the smaller size of the Short AN group than the Long AN one may account for differences in detecting cortical modifications between them.

Overall, our results suggest that sulcal morphology measures have a good ability in detecting the presence of cortical morphological alterations in the acute phases of anorexia nervosa. The absence of significant differences in sulcal morphology measures between patients who recovered from the disorder and HW suggests that these cortical modifications are unlikely to be a trait or scar of AN.

This study had some limitations but also several strengths. First, the cross-sectional design of the research does not allow for causal inferences, and longitudinal investigations are needed to confirm these findings. Second, BMI is scarcely accurate in quantifying malnutrition; therefore, other parameters like weight suppression or weight suppression speed should be considered to account for its role in affecting the cortical structure (Solmi et al., 2018). Third, absence of males in the sample does not allow any inference about the presence of cortical alterations in male patients with AN. Nevertheless, this is, to our knowledge, the first study that examines sulcal width and gyrification gradient in AN, thus integrating previous observations with parameters that can provide novel information about cortical structure. The presence of a relationship between gyrification gradient and sulcal morphology values support the presence of common causal determinants in the alterations of these two indices and highlights the importance of analyzing cortical morphology in AN by employing different and non-redundant parameters.

In conclusion, our study evidenced the presence of higher width in specific cortical sulci in patients with acute AN, which is confirmed and summarized by the results of a factorial analysis. Patients with a duration of the disorder longer than 1 year showed similar patterns of sulcal alterations when compared to HW than patients with a shorter duration of the disorder. Significant associations between areas where the gyrification gradient is altered in the three groups of acute AN patients (Whole AN, Short AN, and Long AN) and specific sulcal width measures emerged.

Declaration of Competing Interest

The authors declare no conflict of interest

Supplementary materials

Supplementary material associated with this article can be found, in the online version, at [10.1016/j.psychres.2021.111350](https://doi.org/10.1016/j.psychres.2021.111350).

References

- Alemán-Gómez, Y., Janssen, J., Schnack, H., Balaban, E., Pina-Camacho, L., Alfaró-Almagro, F., Castro-Fornieles, J., Otero, S., Baeza, I., Moreno, D., Bargalló, N., Parellada, M., Arango, C., Desco, M., 2013. The human cerebral cortex flattens during adolescence. *J. Neurosci.* 33, 15004–15010. <https://doi.org/10.1523/JNEUROSCI.1459-13.2013>.

- American Psychiatric Association, Of, M., Disorders, M., 2013. Diagnostic and statistical manual of mental disorders: DSM-5. Arlington. <https://doi.org/10.1176/appi.books.9780890425596.744053>.
- Armstrong, E., Schleicher, A., Omran, H., Curtis, M., Zilles, K., 1995. The ontogeny of human gyrification. *Cereb. Cortex*. 5, 56–63. <https://doi.org/10.1093/cercor/5.1.56>.
- Artmann, H., Grau, H., Adelman, M., Schleiffer, R., 1985. Reversible and non-reversible enlargement of cerebrospinal fluid spaces in anorexia nervosa. *Neuroradiology*. 27, 304–312. <https://doi.org/10.1007/BF00339562>.
- Bernardoni, F., King, J.A., Geisler, D., Birkenstock, J., Tam, F.I., Weidner, K., Roessner, V., White, T., Ehrlich, S., 2018. Nutritional status affects cortical folding: lessons learned from anorexia nervosa. *Biol. Psychiatry*. <https://doi.org/10.1016/j.BIOPSYCH.2018.05.008>.
- Cascino, G., Canna, A., Monteleone, A.M., Russo, A.G., Prinster, A., Aiello, M., Esposito, F., Salle, F.Di, Monteleone, P., 2020. Cortical thickness, local gyrification index and fractal dimensionality in people with acute and recovered Anorexia Nervosa and in people with Bulimia Nervosa. *Psychiatry Res. - Neuroimaging*. <https://doi.org/10.1016/j.psychres.2020.111069>.
- Collantoni, E., Elena, T., Marco, S., Paolo, M., Enrica, M., Federico, D., Stefano, G., Giovanni, A.D., Renzo, M., Angela, F., 2020a. Hippocampal volumes in anorexia nervosa at different stages of the disorder. *Eur. Eat. Disord. Rev.* <https://doi.org/10.1002/erv.2806>.
- Collantoni, E., Madan, C.R., Meneguzzo, P., Chiappini, I., Tenconi, E., Manara, R., Favaro, A., 2020b. Cortical complexity in Anorexia Nervosa: a fractal dimension analysis. *J. Clin. Med.* 9, 833. <https://doi.org/10.3390/jcm9030833>.
- Collantoni, E., Meneguzzo, P., Tenconi, E., Manara, R., Favaro, A., 2019. Small-world properties of brain morphological characteristics in Anorexia Nervosa. *PLoS ONE*. 14, e0216154 <https://doi.org/10.1371/journal.pone.0216154>.
- Couzin-Frankel, J., 2020. Rethinking anorexia. *Science* (80) 368, 124–127. <https://doi.org/10.1126/science.368.6487.124>.
- Favaro, A., 2013a. Brain development and neurocircuit modeling are the interface between genetic/environmental risk factors and eating disorders. A commentary on keel & forney and friederich et al. *Int. J. Eat. Disord.* <https://doi.org/10.1002/eat.22131>.
- Favaro, A., Clementi, M., Manara, R., Bosello, R., Forzan, M., Bruson, A., Tenconi, E., Degortes, D., Titton, F., Di Salle, F., Santonastaso, P., 2013b. Catechol-O-methyltransferase genotype modifies executive functioning and prefrontal functional connectivity in women with anorexia nervosa. *J. Psychiatry Neurosci.* 38, 241–248. <https://doi.org/10.1503/jpn.120068>.
- Favaro, A., Tenconi, E., Degortes, D., Manara, R., Santonastaso, P., 2015. Gyrification brain abnormalities as predictors of outcome in anorexia nervosa. *Hum. Brain Mapp.* 36, 5113–5122. <https://doi.org/10.1002/hbm.22998>.
- Fischl, B., 2012. FreeSurfer. *Neuroimage*. <https://doi.org/10.1016/j.neuroimage.2012.01.021>.
- Fischl, B., Sereno, M.I., Dale, A.M., 1999. Cortical surface-based analysis: II. Inflation, flattening, and a surface-based coordinate system. *Neuroimage*. <https://doi.org/10.1006/nimg.1998.0396>.
- Janssen, J., Alemán-Gómez, Y., Schnack, H., Balaban, E., Pina-Camacho, L., Alfaro-Almagro, F., Castro-Fornieles, J., Otero, S., Baeza, I., Moreno, D., Bargalló, N., Parellada, M., Arango, C., Descio, M., 2014. Cortical morphology of adolescents with bipolar disorder and with schizophrenia. *Schizophr. Res.* 158, 91–99. <https://doi.org/10.1016/j.schres.2014.06.040>.
- King, J.A., Frank, G.K.W., Thompson, P.M., Ehrlich, S., 2018. Structural neuroimaging of Anorexia Nervosa: future directions in the quest for mechanisms underlying dynamic alterations. *Biol. Psychiatry*. <https://doi.org/10.1016/j.biopsych.2017.08.011>.
- Kochunov, P., Mangin, J.F., Coyle, T., Lancaster, J., Thompson, P., Rivière, D., Cointepas, Y., Régis, J., Schlosser, A., Royall, D.R., Zilles, K., Mazziotta, J., Toga, A., Fox, P.T., 2005. Age-related morphology trends of cortical sulci. *Hum. Brain Mapp.* 26, 210–220. <https://doi.org/10.1002/hbm.20198>.
- Lavagnino, L., Amianto, F., Mwangi, B., D'Agata, F., Spalatro, A., Zunta Soares, G.B., Daga, G.A., Mortara, P., Fassino, S., Soares, J.C., 2016. The relationship between cortical thickness and body mass index differs between women with anorexia nervosa and healthy controls. *Psychiatry Res. - Neuroimaging*. 248, 105–109. <https://doi.org/10.1016/j.psychres.2016.01.002>.
- Madan, C.R., 2021. Age-related decrements in cortical gyrification: evidence from an accelerated longitudinal dataset. *Eur. J. Neurosci.* 53, 1661–1671. <https://doi.org/10.1111/ejn.15039>.
- Lavagnino, L., Mwangi, B., Cao, B., Shott, M.E., Soares, J.C., Frank, G.K.W., 2018. Cortical thickness patterns as state biomarker of anorexia nervosa. *Int J Eat Disord.* Mar, Epub 2018 Feb 7. PMID: 29412456; PMCID: PMC5843530. 51 (3), 241–249. <https://doi.org/10.1002/eat.22828>.
- Madan, C.R., 2019. Robust estimation of sulcal morphology. *Brain Informatics*. 6, 1–11. <https://doi.org/10.1186/s40708-019-0098-1>.
- Madan, C.R., Kensinger, E.A., 2018. Predicting age from cortical structure across the lifespan. *Eur. J. Neurosci.* 47, 399–416. <https://doi.org/10.1111/ejn.13835>.
- Madan, C.R., Kensinger, E.A., 2016. Cortical complexity as a measure of age-related brain atrophy. *Neuroimage*. 134, 617–629. <https://doi.org/10.1016/j.neuroimage.2016.04.029>.
- Magnotta, V.A., 1999. Quantitative in vivo measurement of gyrification in the human brain: changes associated with aging. *Cereb. Cortex*. <https://doi.org/10.1093/cercor/9.2.151>.
- McDonough, I.M., Madan, C.R., 2020. Structural complexity is negatively associated with brain activity: a novel multimodal test of compensation theories of aging. *Neurobiol. Aging*. <https://doi.org/10.1016/j.neurobiolaging.2020.10.023>.
- Miller, J.A., Voorhies, W.L., Lurie, D.J., D'Esposito, M., Weiner, K.S., 2021. Overlooked tertiary sulci serve as a meso-scale link between microstructural and functional properties of human lateral prefrontal cortex. *J. Neurosci.* <https://doi.org/10.1523/JNEUROSCI.2362-20.2021>.
- Nickel, K., Joos, A., Tebartz van Elst, L., Holovics, L., Endres, D., Zeeck, A., Maier, S., 2019. Altered cortical folding and reduced sulcal depth in adults with anorexia nervosa. *Eur. Eat. Disord. Rev.* 27, 655–670. <https://doi.org/10.1002/erv.2685>.
- Sandu, A.-L., Izard, E., Specht, K., Beneventi, H., Lundervold, A., Ystad, M., 2014. Post-adolescent developmental changes in cortical complexity. *Behav. Brain Funct.* 10, 44. <https://doi.org/10.1186/1744-9081-10-44>.
- Schaer, M., Cuadra, M.B., Schmansky, N., Fischl, B., Thiran, J.P., Eliez, S., 2012. How to measure cortical folding from MR images: a step-by-step tutorial to compute local gyrification index. *J. Vis. Exp.* Jan 2, PMID: 22230945, PMCID: PMC3369773. 2 (59) <https://doi.org/10.3791/3417>.
- Schultz, C.C., Wagner, G., de la Cruz, F., Berger, S., Reichenbach, J.R., Sauer, H., Bär, K. J., 2017. Evidence for alterations of cortical folding in anorexia nervosa. *Eur. Arch. Psychiatry Clin. Neurosci.* 267, 41–49. <https://doi.org/10.1007/s00406-015-0666-1>.
- Solmi, M., Gallicchio, D., Collantoni, E., Meneguzzo, P., Zanetti, T., Degortes, D., Tenconi, E., Bonello, E., Veronese, A., Ronzan, A., Favaro, A., 2018. The impact of weight suppression and weight loss speed on baseline clinical characteristics and response to treatment. *Int. J. Eat. Disord.* 51, 542–548. <https://doi.org/10.1002/eat.22861>.
- Thambisetty, M., Wan, J., Carass, A., An, Y., Prince, J.L., Resnick, S.M., 2010. Longitudinal changes in cortical thickness associated with normal aging. *Neuroimage* 52, 1215–1223. <https://doi.org/10.1016/j.neuroimage.2010.04.258>.
- Treasure, J., Stein, D., Maguire, S., 2015. Has the time come for a staging model to map the course of eating disorders from high risk to severe enduring illness? An examination of the evidence. *Early Interv. Psychiatry*. <https://doi.org/10.1111/eip.12170>.
- White, T., Andreasen, N.C., Nopoulos, P., Magnotta, V., 2003. Gyrification abnormalities in childhood- and adolescent-onset schizophrenia. *Biol Psychiatry*. Aug 15, PMID: 12915286. 54 (4), 418–426. [https://doi.org/10.1016/s0006-3223\(03\)00065-9](https://doi.org/10.1016/s0006-3223(03)00065-9).
- White, T., Su, S., Schmidt, M., Kao, C.Y., Sapiro, G., 2010. The development of gyrification in childhood and adolescence. *Brain Cogn.* <https://doi.org/10.1016/j.bandc.2009.10.009>.
- Zipfel, S., Giel, K.E., Bulik, C.M., Hay, P., Schmidt, U., 2015. Anorexia nervosa: aetiology, assessment, and treatment. *The Lancet Psychiatry* 2, 1099–1111. [https://doi.org/10.1016/S2215-0366\(15\)00356-9](https://doi.org/10.1016/S2215-0366(15)00356-9).